

## Use of Motion Lab Analysis for Upper Extremity Cerebral Palsy Surgery: Pronator Teres Rerouting versus Release.

Ann VanHeest, MD<sup>1,2</sup>, Jean Stout, MS, PT<sup>1</sup>, Tom Novacheck, MD<sup>1,2</sup>

<sup>1</sup> Gillette Children's Specialty Healthcare, St. Paul, USA

<sup>2</sup> University of Minnesota, Dept. Orthopaedic Surgery, Minneapolis, USA

### Introduction


Clinical decision making for children with cerebral palsy who have upper extremity dysfunction has traditionally relied solely on clinical evaluation and the assessment of function. It is often difficult in the presence of limited active movement to determine whether a re-routing vs. lengthening procedure for a muscle such as the pronator teres would be most beneficial in restoring function. This study presents the use of motion lab analysis in pre-operative evaluation of the pronator teres for treatment of pronation deformity in cerebral palsy.

### Statement of Clinical Significance

The presence of phasic vs. non-phasic muscle activity in the pronator teres muscle may influence surgical decision-making whether consideration of a re-routing procedure is warranted.

### Methodology

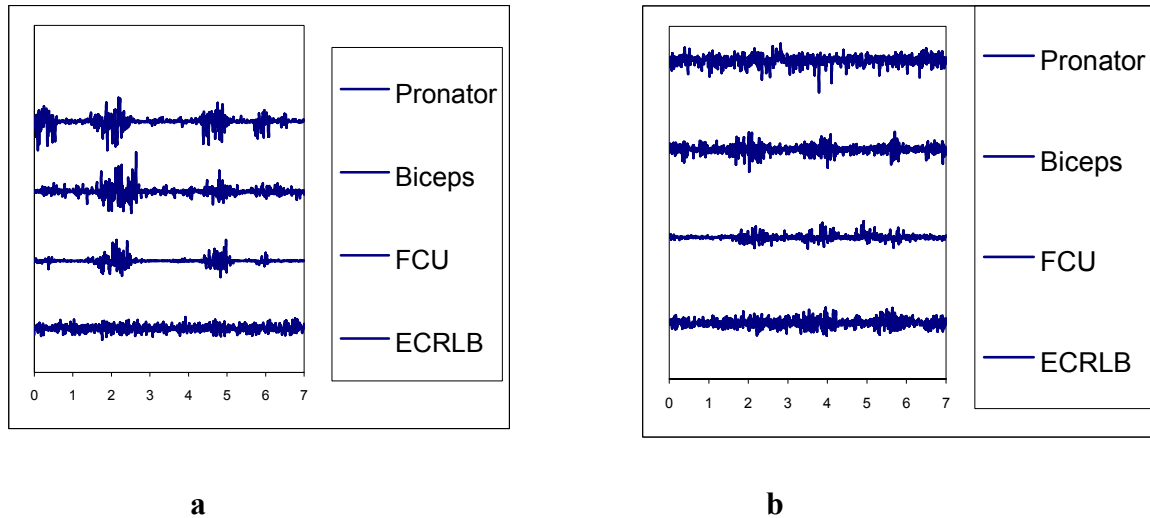
Fifteen children underwent pre-operative motion lab analysis with fine needle electrodes placed in the pronator teres and flexor carpi ulnaris and surface electrodes on the biceps femoris and radial wrist extensors. EMG activity was monitored and simultaneously synchronized to a split screen video recording while the child performed the Jebsen-Taylor Test of Hand Function [1]. See Figure 1. Results were analyzed as to whether the pronator teres was a spastic deforming muscle or exhibited volitional control with activity.



**Figure 1:** Synchronized EMG + video during a checker task of the Jebsen-Taylor Test of Hand Function.

## Results

Seven children exhibited volitional control as indicated by phasic activity of the pronator muscle during activities. Figure 2a. These children were surgically treated with a pronator teres re-routing; Eight children exhibited primarily spasticity as indicated by continuous, non-phasic activity of the muscle during activities. Figure 2 b. These children were surgically treated with pronator teres release.



**Figure 2:** Representative tracings from EMG exhibiting a) phasic activity and b) continuous muscle activity in the pronator teres muscle.

The seven children treated with pronator teres re-routing (phasic EMG activity) were an average age of 9.7 years old (8-14) and had an average of 2.8 other simultaneous reconstructive procedures. Their average pre-operative AROM was 86° pronation and -4° supination. At an average follow-up of 21 months (3-46), the average post-operative AROM was 59° pronation and 54° supination. The eight children treated with pronator teres release (continuous EMG firing) were an average age of 13 years old (6-19) and had an average of 3.7 other simultaneous reconstructive procedures. Their average pre-operative AROM was 90° pronation and -10° supination. At an average follow-up of 22 months, the average post-operative AROM was 69° pronation and 48° supination.

## Conclusion

The authors conclude that the motion lab analysis was a useful tool in the pre-operative assessment of the pronator teres muscle and aided in decision making between a re-routing transfer versus a release of the muscle. Comparison of the results of the two treatment groups shows clinically similar results.

## References

1. Jebsen, R et al., *Archiv Phys Med Rehabil* 31: 311-328, 1969